



**Expression of programmed death ligand 1 (PD-L1) in urothelial bladder carcinoma
(immunohistochemical and histopathological study)**

*Nadia Ahmed Abd El-Moeze^a, Marwa Mohamed Sayed^a, Amr Medht Masoud^b, Samira AbdAllah
Mahmoud^c, Wesam Ismail Moustafa^a*

^a Pathology department, Faculty of medicine, Beni- Suef University, Beni-Suef, 62514, Egypt

^b Urology department, Faculty of medicine, Beni- Suef University, Beni-Suef, 62514, Egypt

^c Pathology department, Faculty of medicine, Cairo University, Cairo, 11865, Egypt

Abstract:

The aim of this work is to evaluate the immunohistochemical expression of PD-L1 in tumor cells of urothelial bladder carcinoma. PD-L1 immunoexpression was assessed on 20 cases of radical cystectomy specimens using monoclonal rabbit anti- PD-L1 antibody. Extent of membranous PD-L1 expression was assigned in each case. Tumor cells showing > 5% expression were considered positive. PD-L1 was seen in 6 (30%) cases [1 case score +2 and 5 cases score +3], while 14(70%) cases were negative [7 cases score 0 and 7 cases score +1]. PD-L1 expression in tumor cells was insignificantly correlated with different available clinicopathological parameters such as sex, pathological stage, associated bilharzial infestation, necrosis, perineural invasion and associated tumor infiltrating mononuclear cells (TIMCs), although PD-L1 positivity tend to predominate in advanced pathological stage of tumor (T3 and T4). These findings may have clinical implications for the management of patients with PD-L1 positive urothelial bladder carcinoma.

Keywords: PDL-1; UBC; Immunohistochemistry.

1. Introduction:

Urinary bladder carcinoma (UBC) is the ninth most common cancer worldwide and ranks 13th in terms of deaths ranks. The highest incidence rates observed in North America, Southern and Western Europe as well as in certain countries in Northern Africa

or Western Asia. The lowest incidence rates were found in Central and South America, Sub-Saharan Africa, and South East Asia. A strong male predominance is observed with three-quarters of all UBC cases occurring in men [1].

In Egypt, UBC is classified as the third malignancy after breast and colorectal cancers; most cases are urothelial cell carcinomas (78.0%). Moreover, Egyptian males have the highest mortality rates (16.3 per 100,000), which is twice as high as the highest rates in Europe and over 4 times higher than that in the United States [2&3]. The major risk factor for bladder carcinoma is cigarette smoking. Also, certain occupational, industrial exposures and schistosomal infection (particularly in Egypt) are another major factor [4].

The essential function of the immune system is its ability to differentiate between self and non-self; For this purpose, the immune system depends on multiple “checkpoints”, which are molecules on certain immune cells that need to be activated or inactivated to start an immune reaction [5]. In the setting of malignancy, multiple mechanisms of immune suppression may exist that prevent effective antitumor immunity [6].

The mechanism of tumor cell escape may be owing to decrease in neo-antigen presentation, release of cytokines by recruited regulatory T cells that promotes an immunosuppressive tumor microenvironment, or up-regulation of negative co-signals which prevent effector T-cell activation, thus allowing ongoing tumor growth. This route is described as the cancer-immunity cycle [7].

Overexpression of immune checkpoint molecules affects tumor-specific T-cell immunity in the cancer microenvironment and

can reshape tumor progression and metastasis [8]. Three checkpoint molecules have been studied most extensively and become clinically important targets of drug therapy are programmed cell death (PD)-1, PD-ligand-1 (PD-L1) and cytotoxic T-lymphocyte associated protein 4 (CTLA-4) [7]. PD-L1 is a member of B7 family also called B7-H1 [9]. PD-L1 is a type 1 transmembrane protein which is known to suppress the immune system in cancer, [7].

Numerous human cancers have also been reported to aberrantly express PDL-1, including glioblastoma, melanoma, non-small cell lung cancer, cancers arising from the colon, ovary, head and neck, and breast [10]. In urothelial carcinoma there was remarkable expression of PD-L1; higher PD-L1 expression in tumor cells was associated with the presence of advanced disease [11].

Cancer immunotherapy using immune checkpoint blockade has become an exciting and promptly developing subject in cancer management with new, targeted therapies exhibiting anti-neoplastic activity and survival benefits across multiple tumor types [12].

As regarding the previous knowledge, we perform this work; to estimate the PD-L1 immunohistochemical expression in urothelial bladder carcinoma in tumor cells to detect any special clinicopathologic features among Egyptian patients.

2. Material and Methods:

The included cases in this study were twenty cases managed by radical cystectomy collected from the Pathology Department, Faculty of Medicine, Beni- Suef University during the period from May 2017 to May 2018 chosen according to the following exclusion criteria: cases with missing data, marked autolysis, poor processing, widely necrotizing tumor tissue.

Clinicopathological data and representative paraffin blocks were attained. The patient's age ranged from 30 to 75 years old with a mean age of 62.95 ± 10.6 SD. About 80% of patients (17 cases) were ≥ 60 years.

2.1 Histopathological examination:

Histopathological examination of H and E stained slides was performed for the confirmation of diagnosis for the tumor type and grade according to the WHO histological classification of tumors of the urinary tract [13]. Tumors were staged according to the Tumor Node Metastasis (TNM) system of the American Joint Committee on Cancer (AJCC) [14].

2.2 PD-L1 immunohistochemical staining and evaluation:

Section from each case was stained immunohistochemically by using rabbit monoclonal antibody directed against PD-L1 (clone ZR3, Cat. No. 438R-28, CELL MARQUE, USA). Fully automated staining

was carried out on the BenchMark Gx from Ventana. Parallel sections of tonsil tissue were used as a positive control. The tumor tissue sections were examined using light microscopy as well as digital slide scanner (Leica APERIO LV1 microscopy) for the expression of PD-L1 in malignant urothelial cells. PD-L1 positivity was considered by the presence of membranous brown immunostaining with a cutoff value $>5\%$ of tumor cells. Isolated cytoplasmic staining was considered negative [15&16].

Interpretation of PDL-1 positivity:

The expression of PDL-1 and percentage of staining tumor cells were assessed and scored from 0 to +3 using the following system: score 0 (positive cells were $\leq 1\%$), score +1 (positive cells were $>1\%$ and $\leq 5\%$), score +2 (positive cells were $>5\%$ and $\leq 10\%$) and score +3 (positive cells were $>10\%$). Cases with a score of +2 or +3 were considered positive [15&7].

Data Analysis:

Data were coded and entered using the SPSS (Statistical Package for the Social Sciences) version 25. Descriptive statistics for the demographic and pathological characteristics of cases were first analyzed. Chi square (2%) test was performed. P-values equal to or less than 0.05 were considered statistically significant.

3. Results:

In our study, most of studied cases (80%) were males, 16 out of 20 cases with male: female ratio 4:1. with a mean age of 62.95 years and a mean tumor size of 4.25 cm. All cases were high grade urothelial carcinoma. Regarding the extent of primary tumor (T); 10 cases (50%) were T2. For lymph node status (N); we found that 55% of the cases were N0. In present study PD-L1 expression in tumor cells was detected in 6 (30%) out of 20 urothelial carcinoma cases [1 case score +2 and 5 cases score +3], while 14 (70%) cases were negative [7 cases score 0 and 7 cases score +1]. The present study did not show a significant relation with gender of patients, bilharzial infestation, perineural invasion and tumor necrosis (Table1). Also, this study revealed that no statistical significance between PDL-1 (expression & score) and pathological tumor stage as well as lymph node metastasis (pN) stage in the studied cases (P-value 0.16 and 0.73, respectively, although PDL-1 positivity was noted among higher pathological stages T3 and T4

(Table1).

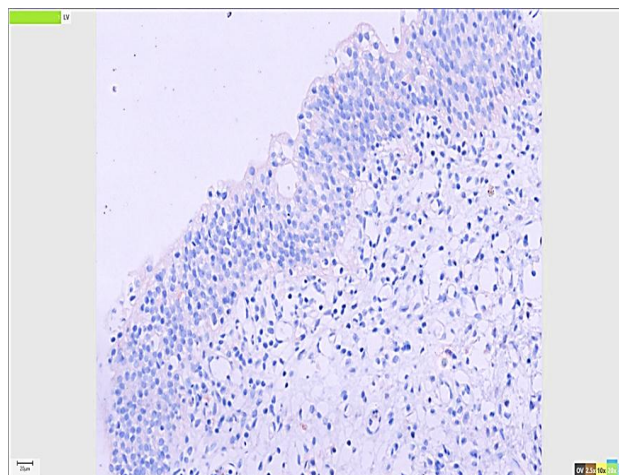


Figure (1): Normal urothelium showing negative PDL-1 expression (score 0) (IHC x 20)

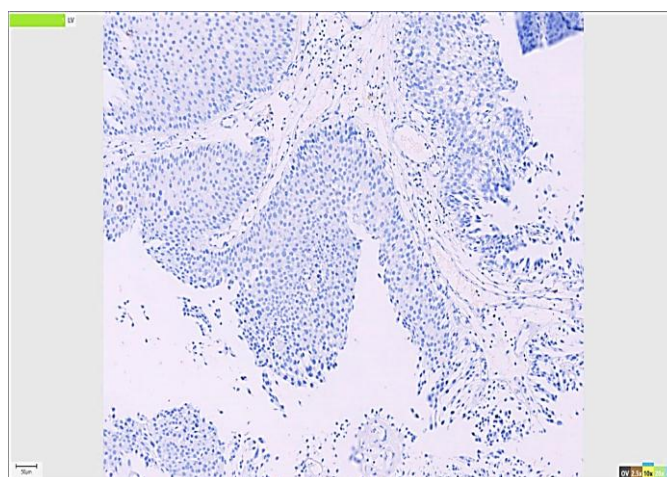


Figure (1): Dysplastic urothelium showing negative PDL-1 expression (score 0) (IHC x 10)

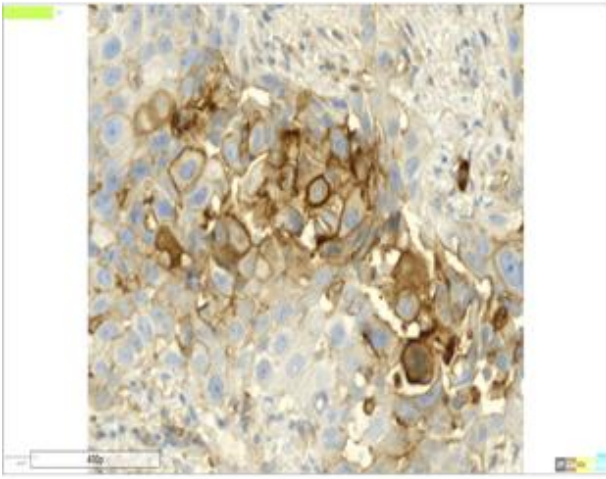


Figure (3): High power view of positive PDL-1 membranous staining in urothelial carcinoma

(score +1) ($\leq 5\%$) (IHC x 40)

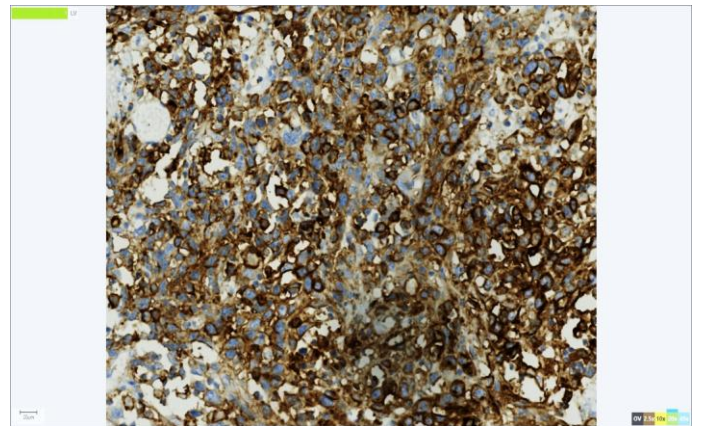


Figure (3): Positive membranous staining of PDL-1 in a case of invasive high grade urothelial carcinoma with (score +3) ($>10\%$) (IHC x20)

Parameter	NO	Negative		Positive		P value	
		%	Score 0	Score 1+	Score 2+		Score 3+
Total	20	100%	7	7	1	5	
			35%	35%	5%	25%	
Gender	Male	16	6	5	0	5	0.12
			80%	30%	25%	0%	
	Female	4	1	2	1	0	
			20%	5%	10%	5%	0%
Bilharziasis	Present	7	2	4	0	1	0.45
			35%	10%	20%	0%	
	Absent	13	5	3	1	4	
			65%	25%	15%	5%	20%
Perineural invasion	Absent	13	5	5	1	2	0.54
			65%	25%	25%	5%	
	Present	7	2	2	0	3	
			35%	10%	10%	0%	15%
Tumor necrosis	Absent	6	2	3	1	0	0.17
			30%	10%	15%	5%	
	Present	14	5	4	0	5	
			70%	25%	20%	0%	25%
Extent of TIMCs by H&E	Mild	6	4	1	0	1	0.49
			30%	20%	5%	0%	
	Moderate	12	3	4	1	4	

		60%	15%	20%	5%	20%	
	Severe	2	0	2	0	0	
		10%	0%	10%	0%	0%	
Tumor	T2	10	6	2	1	1	
(pT) stage		50%	30%	10%	5%	5%	
	T3	7	1	4	0	2	0.16
		35%	5%	20%	0%	10%	
	T4	3	0	1	0	2	
		15%	0%	5%	0%	10%	
Pathological	Negative	11	3	4	1	3	0.73
(pN) stage		55%	15%	24%	5%	15%	
	Positive	9	4	3	0	2	
		45%	20%	15%	0%	10%	

Table 1: Expression and score of PDL-1 in tumor cells of the studied urothelial carcinoma cases

4. Discussion:

Patients of bladder carcinoma can manifest acquired immune dysfunction that seems to affect lymphocytes and is related to tumor stage. Also host immunity appears to modify bladder cancer pathogenesis [17].

PD-L1 contributes to host immune evasion to promote localized stage progression of urothelial malignancies towards progressively deadly tumors [18].

The potential role of cancer neoantigens in immune regulation of cancer suggests that urothelial carcinoma may be

particularly suitable for checkpoint blockade [7].

In our study (20 cases) were stained by anti- PD-L1 monoclonal antibody for immunohistochemical evaluation where only membranous staining of PD-L1, in more than 5% of tumor cells were considered positive. Normal urothelium and non-invasive lesions were negative for PDL-1 expression these results were in agreement of [16].

We found positive PD-L1 IHC expression in tumor cells was detected in 30% (6 cases) and 70% (14 cases) were negative PD-L1 expression (Table1), this is closely to the study done by [15] who demonstrated that positive PD-L1 expression was detected in 20% (32/160) of patients. While the study done by [19] found PD-L1 IHC membranous expression in 28% (77/280) with a lower cutoff of 1%. Our finding is uncoordinated with lower results elicited by [11] who demonstrated a relatively lower PD-L1 membranous IHC expression of 12.4% of UC in a large cystectomy cohort, using a similar 5% cutoff. In contrast the study done by [19] reported membranous and cytoplasmic PD-L1 expression in all 65 UCs analyzed, frozen tissue rather than formalin fixed paraffin embedded was used and a monoclonal antibody (MIH1, mouse IgG1) was used in their study; these may explain the differences in results. In this study, there was no statistically significant relationship between PD-L1 immunostaining and the gender of the patients (p-value 0.12), (Table 1). Our results are agreed with that obtained in previous study performed by [16] and [19] who assessed that there was no association between PD-L1 expression and the gender (p-value 0.1 and 0.99 respectively). In this study there were no statistically significant differences between PD-L1 immunostaining in tumor cells and pathological (pT) stage, p-value 0.16 (Table 1). This result is compatible with the studies done

by [15] and [18] who found that there were no statistically significant differences in PD-L1 expression and pathological (pT) stage (p-value 0.25 and 0.78, respectively). In difference to our findings, the study performed by [19] recorded that tumor-associated PD-L1 expression was associated significantly (p-value 0.031) with the pathological (pT) stage. Our results showed that no statistically significant differences between PD-L1 immunostaining in tumor cells and lymph node metastasis (pN) stage (P-value 0.73) (Table 1), This in agreement with relevant study performed by [16] and [19] who reported that no significant association was found between PD-L1 expression and pathological (pN) stage P-value 1.0 and 0.38, respectively. Our results showed there was no statistically significant relationship between PD-L1 immunohistochemical staining in tumor cells and associated TIMCs by H&E staining p-value 0.49 (Table 1). These results were not in agreement with [18]; they reported that PD-L1 expression was associated with the presence of intratumoral lymphocytic infiltration (p-value 0.004). There was no statistically significant relationship between PD-L1 immunostaining and associated tumor necrosis (p-value 0.17) (Table 1), There were no other studies discussing this point to compare with our results. in urothelial carcinoma, but [21] reported that PD-L1 expression in clear cell renal cell carcinoma tumors correlates with coagulative necrosis. Regarding the

relationships between PD-L1 immunostaining and the following (presence of bilharziasis and perineural invasion) (p-value 0.45 and 0.54 respectively) (Table 1) up to our knowledge this is an original work and there is no literature conferring the above findings

5. Conclusion and Recommendations:

- The current research pointed that 30% of studied cases were positive for PD-L1 expression.
- Expression of PD-L1 was detected among advanced pathological (pT) stage.
- Assessment of PD-L1 immunostaining status can be used to recognize patients who may benefit from targeted immunotherapy after radical cystectomy.
- Further studies with larger samples are recommended to establish the prognostic significance of PD-L1 to provide targeted therapy.

6. References:

1. Antoni, S., Ferlay, J., Soerjomataram, I., Znaor, A., Jemal, A., & Bray, F. (2017). Bladder cancer incidence and mortality: a global overview and recent trends. *European urology*, 71(1), 96-108.
2. Ferlay J, Shin H R, Bray F et al., (2008): *Cancer Incidence and Mortality Worldwide: IARC Cancer Base No. 10*. Lyon, France: International Agency for Research on Cancer.
3. Helal, T., Salman, M., & Ezz-Elarab, S. (2015). Pathology-based cancer registry 2001-2010. Chapter, 4, 17-25.
4. ElMoneim, H. M. A., Tawfik, H. M., El Sherbiny, Y. M., & Tawfik, E. R. (2011). Analysis of Her2/neu overexpression and amplification in urothelial carcinoma of the bladder associated with Cox-2 overexpression. *Int J Cancer Res*, 7(1), 8-24.
5. Johansson, H., Andersson, R., Bauden, M., Hammes, S., Holdenrieder, S., & Ansari, D. (2016). Immune checkpoint therapy for pancreatic cancer. *World journal of gastroenterology*, 22(43), 9457.
6. Postow, M. A., Callahan, M. K., & Wolchok, J. D. (2015). Immune checkpoint blockade in cancer therapy. *Journal of Clinical Oncology*, 33(17), 1974.
7. Bidnur, S., Savdie, R., & Black, P. (2016). Inhibiting immune checkpoints for the treatment of bladder cancer. *Bladder Cancer*, 2(1), 15-25.
8. Carosella, E. D., Ploussard, G., LeMaoult, J., & Desgrandchamps, F. (2015). A systematic review of immunotherapy in urologic cancer: evolving roles for targeting of CTLA-4, PD-1/PD-L1, and HLA-G. *European urology*, 68(2), 267-279.
9. Zou, W., & Chen, L. (2008). Inhibitory B7-family molecules in the tumour

- microenvironment. *Nature Reviews Immunology*, 8(6), 467-477.
10. Purdie, C., Quinlan, P., Jordan, L., Ashfield, A., Ogston, S., Dewar, J., & Thompson, A. (2014). Progesterone receptor expression is an independent prognostic variable in early breast cancer: a population-based study. *British journal of cancer*, 110(3), 565.
 11. Boorjian, S. A., Sheinin, Y., Crispen, P. L., Farmer, S. A., Lohse, C. M., Kuntz, S. M. & Frank, I. (2008). T-cell coregulatory molecule expression in urothelial cell carcinoma: clinicopathologic correlations and association with survival. *Clinical Cancer Research*, 14(15), 4800-4808.
 12. Herbst, R. S., Soria, J.-C., Kowanetz, M., Fine, G. D., Hamid, O., Gordon, M. S. & Gettinger, S. N. (2014). Predictive correlates of response to the anti-PD-L1 antibody MPDL3280A in cancer patients. *Nature*, 515(7528), 563.
 13. Moch, H., Humphrey, P., Ulbright, T., & Reuter, V. (2016b). Tumours of the urinary tract. *WHO Classification of Tumours of the Urinary System and Male Genital Organs*, 4th ed. Lyon, France: IARC.
 14. Amin, M. B., Greene, F. L., Edge, S. B., Compton, C. C., Gershenwald, J. E., Brookland, R. K. & Winchester, D. P. (2017). The eighth edition AJCC cancer staging manual: continuing to build a bridge from a population-based to a more “personalized” approach to cancer staging. *CA: a cancer journal for clinicians*, 67(2), 93-99.
 15. Bellmunt, J., Mullane, S., Werner, L., Fay, A., Callea, M., Leow, J. & Freeman, G. (2015). Association of PD-L1 expression on tumor-infiltrating mononuclear cells and overall survival in patients with urothelial carcinoma. *Annals of Oncology*, 26(4), 812-817.
 16. Faraj, S. F., Munari, E., Guner, G., Taube, J., Anders, R., Hicks, J. & Drake, C. (2015). Assessment of tumoral PD-L1 expression and intratumoral CD8+ T cells in urothelial carcinoma. *Urology*, 85(3), 703. e701-703. e706.
 17. Mukamel E, Shohat B, Servadio C. Immunological profile of patients with transitional cell carcinoma of the bladder. *Br J Urol*. 1982;54:11–15
 18. Inman, B. A., Sebo, T. J., Frigola, X., Dong, H., Bergstralh, E. J., Frank, I. & Kwon, E. D. (2007). PD-L1 (B7-H1) expression by urothelial carcinoma of the bladder and BCG-induced granulomata: associations with localized stage progression. *Cancer: Interdisciplinary International Journal of the American Cancer Society*, 109(8), 1499-1505.
 19. Nakanishi, J., Wada, Y., Matsumoto, K., Azuma, M., Kikuchi, K., & Ueda, S. (2007). Overexpression of B7-H1 (PD-L1) significantly associates with tumor grade and postoperative prognosis in

- human urothelial cancers. *Cancer Immunology, Immunotherapy*, 56(8), 1173-1182.
20. Thompson, R. H., Dong, H., & Kwon, E. D. (2007). Implications of B7-H1 expression in clear cell carcinoma of the kidney for prognostication and therapy. *Clinical Cancer Research*, 13(2), 709s-715s