



### Size and Shape of yolk sac as a predictor of pregnancy outcome

Merehan Medhat Hewidy<sup>a</sup>, Mohammed Nagi Mohesen<sup>b</sup>, Hamada Ashry A Ali<sup>b</sup>

a Obstetrics and Gynecology department, Faculty of Medicine, 6 October University, Egypt

b Obstetrics and Gynecology department, Faculty of Medicine, Beni-Suef University, Egypt

#### Abstract:

**Background:** it is estimated that approximately 30% to 40% of implanted pregnancies resulted in spontaneous abortion during the first trimester, most of which occur in very early stage. Significant number of losses predominantly occurs very early in gestation, but once the embryonic heart activity appears the rate of spontaneous abortion gradually decreases to 2-5% . **Methods:** the present study was conducted at the Department of Obstetrics and Gynecology, 6 October Hospital during the period between February 2020 and August 2020 .46 cases at 5 weeks of pregnancy were subjected to transvaginal ultrasound and yolk sac size and shape were determined . Records of pregnant women were registered at 6, 9, 12 weeks of pregnancy. **Aim Of The Work:** to evaluate the value of yolk sac in prediction of pregnancy outcome . **Results:** Abnormal Shape of yolk sac was found in 11 cases, the mean YSD at 6 weeks in aborted cases was  $3.5 \pm 1.8$  and cases who continued pregnancy was  $2.2 \pm 0.4$  and this difference is statistically significant and cut off point at 6 weeks was 2.8 while there was no significant difference between YSD in aborted cases and in those who continued pregnancy at 9,12 weeks respectively. **Conclusion:** large size of yolk sac at 6 weeks of pregnancy and abnormal shape of yolk sac are predictor of poor pregnancy outcome.

**Keywords:** Outcome, Pregnancy, Transvaginal, Yolk sac diameter ,gestational sac diameter.

#### 1. Introduction:

Ultrasonography is one of the most important and useful diagnostic tools in the field of modern medicine. Being non-invasive, safe and without hazards of radiation, it has gained wide acceptability, as an integral part of basic investigative procedures. The

convenience, high portability, rapidity, and accuracy are few of the advantages of ultrasound over the other procedures. In the last two decades, ultrasound has become an essential diagnostic imaging modality in the field of Obstetrics and is being extensively used for evaluation of pregnancy (1).

Accurate differentiation between normal pregnancy and pregnancy loss in early gestation remains a clinical challenge. It is estimated that approximately 30–40% of implanted pregnancies results in spontaneous abortion during first trimester (2)

The various modalities of predicting the pregnancy outcome in the first trimester include the imaging transvaginal ultrasound (TVUS) and biochemical markers . However, these biochemical markers are used only in specific situations for screening of aneuploidy. TVUS on the other hand is a routine baseline procedure done for all pregnancies and parameters like gestational sac diameter, yolk sac diameter, crown rump length, presence of decidual reaction and subchorionic hemorrhage have been used to predict the pregnancy outcome in the first trimester (3).

**Yolk sac is** A membrane-lined sac that provides nourishment in the early stages of development of baby in utero. It also acts as a rudimentary circulatory system before the embryo is able to circulate blood internally (4).

The yolk sac is actively involved in metabolic processes, the formation of immunity and gathers discharges of the fetus. Usually disappears by the end of the 12th week. A recent study suggests that instead of being compressed, it degenerates first and disappears as a result of involution rather than mechanical pressure. Doppler studies demonstrate a decrease in yolk sac vascularity after 9 weeks of gestation. The presence of a

normal yolk sac has been associated with a 62% incidence of a normal pregnancy (5)

## 2. Patients and Methods:

This prospective study include 46 pregnant women at 5 weeks of gestation at onset of the study who underwent trans-vaginal ultrasound to detect yolk sac diameter (YSD), gestational sac diameter (GSD) were measured. Presence/absence of yolk sac (YS) and shape of the yolk sac were noted. Follow up of cases was carried by ultrasound at 6, 9 ,12 weeks of gestation ,end of study was at 12 weeks or if abortion occurred.

**Inclusion criteria;** Singleton pregnancy belonging to gestational age of 5 weeks were included for the study

**Exclusion criteria:** Women with structural anomalies of uterus and cervix, known medical disorders causing abnormal pregnancy outcome i.e. patients with anemia, hyperthyroidism, diabetes mellitus, chronic hypertension, molar pregnancy, Morbid obesity, Multiple pregnancy, cases with history of abdominal truma, Patients refusing for trans-vaginal sonography, who were unwilling for follow up were excluded.

**Scanning technique: ultrasound examination was carried out by** Samsung H 60 The gestational sac and yolk sac were identified,The inner yolk sac diameter was measured by placing calipers at inner margin .

### 3. Results:

This study was conducted on 46 pregnant women at 5 to 6 weeks of gestation who underwent trans-vaginal ultrasound and yolk sac diameter (YSD), gestational sac diameter (GSD) were measured, presence/absence of yolk sac (YS) and shape of the yolk sac were noted. Follow up by ultrasound was done to

confirm fetal well-being and 12 weeks was the cutoff point of success of pregnancy or if abortion occurred before that time.

The mean age of included women was  $28.09 \pm 5.61$  years and mean BMI was  $28.15 \pm 1.41$  kg/m<sup>2</sup> and the mean gravidity was  $2.37 \pm 1.08$  and the mean parity  $1.24 \pm 1.02$

**Table (1):** Distribution of the studied cases according to outcome (n = 46)

Outcome	At 6 wks.		At 9 wks.		At 12 wks.		Final	
	No.	%	No.	%	No.	%	No.	%
Fetal loss	7	15.2	4	10.25	3	8.57	14	30.4
Successful pregnancy	39	84.8	35	76.1	32	69.6	32	69.6

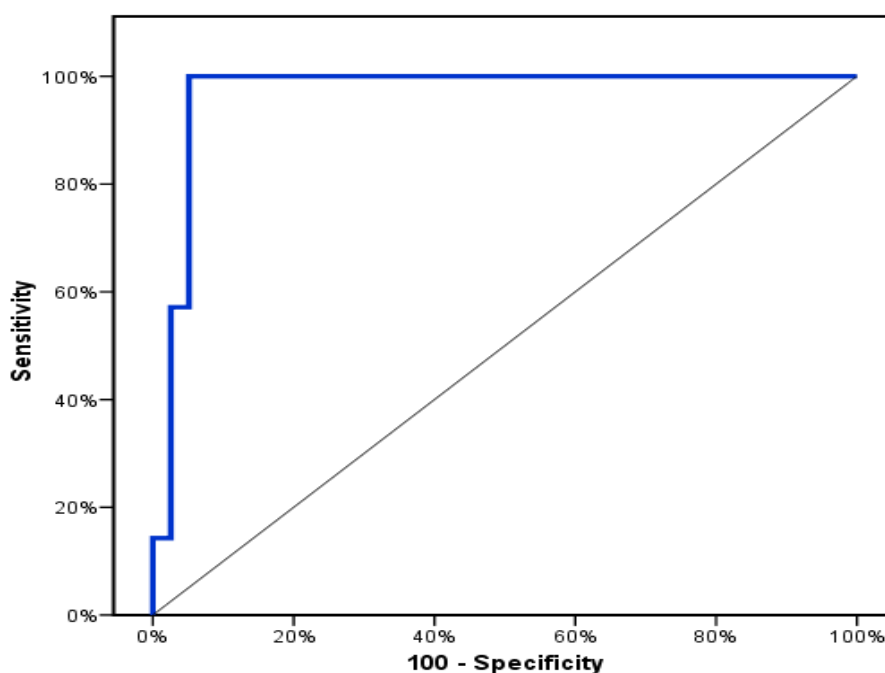
This table shows that fetal loss occurred in 15.2% of cases at 6 weeks and 84.8% had successful pregnancy, at 9 weeks 23.9% fetal loss and 76.1% successful pregnancy and at 12 weeks 30.4% fetal loss and successful pregnancy in 69.6%

**Table (2):** Relation between final outcome and Yolk sac shape

Characteristics	Number (%)	Abortion rates
<b>Abnormal Shape</b>		
Distorted shape	4/46(8.69%)	2(50.0%)
Hypo-echoic rim	4/46(8.69%)	1(25.0%)
Two yolk sac	1/46(2.17%)	0(0.0%)
No yolk sac	1/46(2.17%)	1(100.0%)
Oval shape	1/46(2.17%)	0(0.0%)
<b>Normal Shape</b>	35/46(76.08%)	10(28.57%)

**Table (3):**Relation between final outcome with Yolk sac diameter at 6, 9 and 12 weeks

	Final outcome				P
	Fetal loss		Continued pregnancy		
	No.	%	No.	%	
<b>Yolk sac diameter in (mm) at 6 weeks</b>	(n= 7)		(n= 39)		<0.001*
Min. – Max.	2.8 – 7.5		2.0 – 4.1		
Mean ± SD.	3.5 ± 1.8		2.2 ± 0.4		
Median (IQR)	2.9(2.8 – 2.9)		2.1(2.0 – 2.3)		
<b>Yolk sac diameter in (mm) at 9 weeks</b>	(n= 4)		(n= 35)		0.249
Min. – Max.	3.2 – 5.5		3.1 – 5		
Mean ± SD.	4.1 ± 1		4.6 ± 0.5		
Median (IQR)	3.8(3.4 – 4.8)		4.8(4.5 – 5)		
<b>Yolk sac diameter in (mm) at 12 weeks</b>	(n= 3)		(n= 32)		0.347
Min. – Max.	4.3 – 5.8		4.2 – 5.7		
Mean ± SD.	5.3 ± 0.9		5 ± 0.4		
Median (IQR)	5.8(5 – 5.8)		5.1(4.6 – 5.3)		



**Figure (8) :**ROC curve for Yolk sac diameter to predict successful pregnancy at 6 weeks

#### 4. Discussion:

This study was conducted on 46 pregnant women at 5+0 weeks of gestation who underwent trans-vaginal ultrasound and yolk sac diameter (YSD), gestational sac diameter (GSD) were measured, presence/absence of yolk sac (YS) and shape of the yolk sac were noted. Follow up by ultrasound was done at 6,9,12 weeks to confirm fetal well-being and 12 weeks was the cutoff point of success of pregnancy.

In the current study we found that fetal loss occurred in 15.2% of cases at 6 weeks and 84.8% had continued pregnancy ,at 9 weeks 23.9% fetal loss and 76.1% continued pregnancy and at 12 weeks 30.4% aborted cases and continued pregnancy in 69.6%

In the current study it was observed that on first visit yolk sac was found among 45 cases (97.8% ) and absent in one case ( 2.2%), YS shape was normal in 35 cases and was abnormal in 10 cases the abnormal shape of yolk sac was distorted shape in 4 cases ,hypo\_echoic rim in 4 cases, double yolk sac was found in one case,and oval shape was present in one case.

In the present study 36.36% of cases who had abnormal shape of the yolk sac in early pregnancy ended in abortion while 28.57% of cases with normal shape of yolk sac ended in abortion.

In our study we found that at 6 weeks YSD was statistically higher in aborted cases than in those who continued pregnancy (where the mean diameter of yolk sac was  $3.5\pm 1.8$  mm in aborted cases and in aborted cases the mean diameter of yolk sac who continued pregnancy was  $2.2\pm 0.4$  mm, on the other hand there was statistically insignificant difference between YSD in aborted cases and in those who continued pregnancy at 9 and 12 weeks respectively where the mean YSD in aborted cases at 9 weeks was  $4.1\pm 1$ mm while in cases who continued pregnancy at 9 weeks it was  $4.6\pm 0.5$ mm and in cases who was aborted at 12 weeks it was  $5.3 \pm 0.9$ mm and in successful cases at 12 weeks it was  $5\pm 0.4$ mm

In this respect Rajendiran et al reported progressively increased mean YSD with advanced gestational age between 5- 9 weeks of GA, followed by either their disappearance (73.61%), or decreased size (26.38%) thereafter at 11 weeks of GA in cases with normal outcome.

Srivastava et al showed that Out of 72 cases, yolk sac was seen in 70 cases (97.22%) and it was absent in two cases (2.78%), (7) **and it was in accordance with** Suguna and sukanya (2018) who found that out of 500 patients scanned at recruitment, yolk sac was present in 486 patients (97.8%) and absent in 14 patients (2.8%). Out of 486 cases that were analyzed for YS size and shape, 8 were lost to follow up. Thus, out of 478 cases that were

analyzed for YS size and YS shape and related outcome, 351 (70.2%) and 127 (25.4%) had normal and abnormal shape respectively, 284 (56.8%) and 194 (38.8%) had normal and abnormal size respectively and this results are in agreement with those found in our study.

In consistent with our results, Srivastava et al (2016) discovered that the correlation between yolk sac size and pregnancy outcome is highly significant .

In agreement with our result Sheikh and Anjana showed that the association of abnormal yolk sac diameter with abnormal outcome of pregnancy, while on the other hand there was no clinically significant deference in yolk sac diameter between cases who had been aborted and cases who continued pregnancy at 9 , 12 weeks of pregnancy

Sheikh et al showed that the mean diameter of yolk sac in normal outcome of pregnancy with gestational age group of 6 to 7 weeks was 3.28 mm and for the subsequent gestational age groups, the mean diameter was 3.69 mm, 4.02 mm, 4.25 mm and 5.02 mm respectively at completion of 7, 8, 9, 10 weeks of gestation respectively (1)

Abd Ellatif et al showed that cut off value of yolk sac diameter at 6 and 9 weeks, and the sensitivity, specificity and accuracy to predict the outcome of pregnancy at this cut off value. The cut off value of yolk sac diameter at 6 weeks was more than 4.6, the sensitivity was

81.0%, specificity was 75% and accuracy was 77%. At 9 weeks, the cut off value was more than 5.3, the sensitivity was 32%, specificity was 28% and the accuracy was 30%.

## **5. Conclusion:**

The present study attempted to evaluate the size and shape of yolk sac and its correlation with pregnancy outcome. Absent yolk sac and abnormally large yolk sac at 6 weeks and cases with abnormal shape has higher abortion rate . Abnormalities of the yolk sac size can be used as a good predictive indicator of early pregnancy loss, even before fetal morphology can be studied sonographically. Thus, in the era of artificial reproductive techniques, this parameter may be used as good tool in clinical practice to predict whether a pregnancy is going to have a good or a poor outcome.

## **6. Recommendations:**

- Normal and abnormal sonographic findings related to yolk sac can be used to anticipate the course of pregnancy.
- When an embryo is undetectable, a relatively large yolk sac, even of normal shape, may be an indicator of miscarriage
- Further studies with larger numbers of study groups are needed.

## **7. References:**

1. Sheikh S, Anjana B(2020); A study to assess predictive value of yolk sac diameter by transvaginal sonography with the pregnancy

- outcome. *Int J Reprod Contracept Obstet Gynecol.* Mar;9(3):997-1002
- 2.Papaioannou GI, Syngelaki A, Poon LC et al. (2010); Normal ranges of embryonic length, embryonic heart rate, gestational sac diameter and yolk sac diameter at 6–10 weeks. *Fetal Diagn Ther*,28(4):207–19.
- 3.Suguna B, Sukanya K(2018);Yolk sac size & shape as predictors of first trimester pregnancy outcome: A prospective observational study. *J Gynecol Obstet Hum Reprod* 48:159–164 .
- 4.Donovan MF, Bordoni B,(2020); Embryology, Yolk Sac. [Updated 2020 Mar 29]. In: StatPearls [Internet]. Treasure Island (FL): StatPearls Publishing; 2Jan-.
- 5.Ander SE, Diamond MS, Coyne CB,( 2019); Immune responses at the maternal-fetal interface. *Sci Immunol.*;4 (31): eaat6114.
- 6.Rajendiran S, Thammineni L, Subrahmanian R,et al(2019); Diagnostic significance of total creatine kinase and its isoform in tubal ectopic pregnancy. *The journal of obstetrics and gynaecology research.*39.
- 7.Srivastava G, Nagwani N, Pasricha N et al. (2016); SIZE OF YOLK SAC BY ULTRASONOGRAPHY AND ITS CORRELATION WITH PREGNANCY OUTCOME. *Int J Anat Res, Vol 4(1):2052-57*
- 8.Abd Ellatif EM, Ahmad EK, Halawa MAA, (2018); Yolk Sac Size and Shape, Gestational Sac Diameter and Embryonic Heart Rate as Prognostic Factors for First Trimesteric Outcome. *The Egyptian Journal of Hospital Medicine* .October; Vol. 73 (9), Page 7418-7428