



Effect of Zinc Oxide Nanoparticles on The Spleen of Adult Male Albino Rat and The Possible Protective Role of Selenium: Microanatomical and Biochemical Study.

Sara Abd Eltawab Abd El fadeel¹, Hanan Dawood Yassa¹, Laila Ahmed Rashed², Gaber Hassan Abd El Fattah¹

¹Anatomy and Embryology department, Faculty of Medicine, Beni-Suef University.

²Biochemistry department, Faculty of Medicine, Cairo University.

Abstract:

Thirty five adult male albino rats were used in this study. They were divided into 7 groups: **Group I** (Control), **Group II** (low dose ZnO NPs group), **Group III** (medium dose ZnO NPs group), **Group IV** (high dose ZnO NPs group), **Group V** (low dose ZnO NPs-selenite group), **Group VI** (medium dose ZnO NPs-selenite group), **Group VII** (high dose ZnO NPs-selenite group): tissue of the spleen was examined histopathologically and immunohistochemical, Determination of blood cells count (number of white blood cells (WBCs), red blood corpuscles (RBCs) and platelets. Also tissue level of Hydrogen peroxide (H₂O₂) and paraoxonase-1 (PON-1): for detection of oxidative stress estimated for all groups, PCR detection of apoptosis inducing factor (AIF), apoptotic protease activating factor-1 and caspases 3 and Zinc level in the spleen.

Results of the present study showed that, compared to controls: orally intake of Zinc oxide nanoparticles (ZnO NPs) cause marked changes in spleen tissues as thickening of capsule, thickening of trabeculae, destruction of white pulp and red pulp expansion especially in groups receiving zinc oxide nanoparticles only and these changes markedly decreased on groups receiving selenium as protection.

Keywords: Nanoparticles, ZnO NPs, selenium.

1. Introduction:

Nanoparticles (NPs) are generally defined as particles within the size range of 1–100 nm (1). In research fields, their unique mechanical and physicochemical properties

as a high surface area to volume ratio and abundant reactive sites on the surface make them the most exciting materials when compared with other bulk chemicals (2). In

the meantime, their properties could be the reasons for their interactions with different biological systems (3). Also the materials that are inert in bulk form may become toxic in the nano size form (4).

(5) studied that the orally intake ZnO NPs had toxicity on stomach, liver, pancreas and heart this study is supported by (6). Their initiated pathological mechanisms are inflammation, oxidative stress, fibrosis and DNA damage (7). The histopathological examination of the spleen is highly recommended to evaluate the immune system. In the nano-treated group, thickened stroma, atrophy of white pulps with disappearance of germinal centers, expanded red pulp, also vacuolation and apoptosis of some splenocytes were revealed. Similar observations were reported by (6).

As selenium is an essential trace element, the importance of selenium (Se) in humans is well established, and its deficiency has caused serious health effects in humans, such as Keshan disease. Since its discovery as an important component of antioxidant enzymes, such as glutathione peroxidase (GPx), thioredoxin reductase (TrxR) and iodothyronine deiodinases (IDD), there has been an increased interest in the study of other Se-containing proteins (selenoproteins) or enzymes (selenoenzymes) (8).

The mechanisms of their toxicity are still unclear (9). There-fore, this work aimed to study the possible toxic effects of ZnO NPs in

rat's spleen after their oral administration for two weeks.

2. Material and Methods:

A-Animals:

Thirty five adult male albino rats weighing (150-200 g) were used in the present work. They were housed in standard cages and acclimatized in the laboratory for two weeks before starting the study.

The work was accepted by the Ethics Committee, Faculty of Medicine, Cairo University (2545/2020) and matches the ethical standards of the National Institutes of Health guide for the care and use of Laboratory Animals.

Morphological and behavioral changes in rats were monitored every day. The general health profile was recorded, and the animals were grouped into seven groups (5 rats in each group).

Group I (Control): consists of 5 rats that received no medication and received standard diet only.

Group II (low dose ZnO NPs group): consists of 5 rats that received 100 mg/kg/day zinc oxide nanoparticles by oral gavage (10).

Group III (medium dose ZnO NPs group): consists of 5 rats that received 200 mg/kg/day zinc oxide nanoparticles by oral gavage (10).

Group IV (high dose ZnO NPs group): consists of 5 rats that received 300 mg/kg/day zinc oxide nanoparticles by oral gavage (10).

Group V (low dose ZnO NPs-selenite group): consists of 5 rats that received 100 mg/kg/day zinc oxide nanoparticles by oral gavage and 1.25 mg Se/kg/day by intraperitoneal injection (11).

Group VI (medium dose ZnO NPs-selenite group): consists of 5 rats that received 200 mg/kg/day zinc oxide nanoparticles by oral gavage and 1.25 mg Se/kg/day by intraperitoneal injection (11).

Group VII (high dose ZnO NPs-selenite group): consists of 5 rats that received 300 mg/kg/day zinc oxide nanoparticles by oral gavage and 1.25 mg Se/kg/day by intraperitoneal injection (11).

B-Chemicals:

1-Zinc oxide nanoparticles (ZnO NPs):

Zinc oxide nanoparticles (ZnO NPs) were purchased from Sigma-Aldrich Chemical Co., Egypt in the form of a bottle of 100 g that were dissolved in saline.

2. Sodium biselenite (Se):

Sodium biselenite (Se) was purchased from Sigma Pharmaceuticals Company, Egypt in the form of vials containing 50 g that was dissolved in saline solution.

The drugs were administered once daily for 14 days.

Scarification:

The animals were sacrificed at the end of the 14 days of the experiment by cervical dislocation to avoid chemical injury. The spleen was extracted and collected into PBS and fixed overnight in 40 g/L

paraformaldehyde in PBS at 4 °C. Serial 5- μ m sections of the spleen were stained with hematoxylin and eosin and Masson's Trichrome, and was examined histopathologically and immunohistochemical study.

(A) Paraffin sections were subjected for the following staining procedures:

1- H and E to demonstrate the histological changes (12).

2- Masson's trichrome stain to demonstrate stromal changes in collagen deposition (12).

3-Immunohistochemical study:

a. The anti-proliferating cell nuclear antigen (anti-PCNA) for detection of the proliferative capacity.

b. The anti-p53 factor was performed for detection of apoptosis.

Biochemical study:

1. Determination of blood cells count (number of white blood cells (WBCs), red blood corpuscles (RBCs) and platelets
2. Tissue level of Hydrogen peroxide (H₂O₂) and paraoxonase-1(pon-1): for detection of oxidative stress.
3. PCR detection of apoptosis inducing factor (AIF) and caspases 3
4. Zinc level in the spleen.

Histomorphometric study :

Using Leica image analyzer computer system, the area percent of collagen fibers in Masson's trichrome stained sections will be assessed.

Statistical analysis:

Statistical analysis was performed using statistical package for the social sciences statistical software (SPSS) version 22. Statistical estimation was done using ANOVA followed by Bonferroni pairwise comparisons.

3. Results:

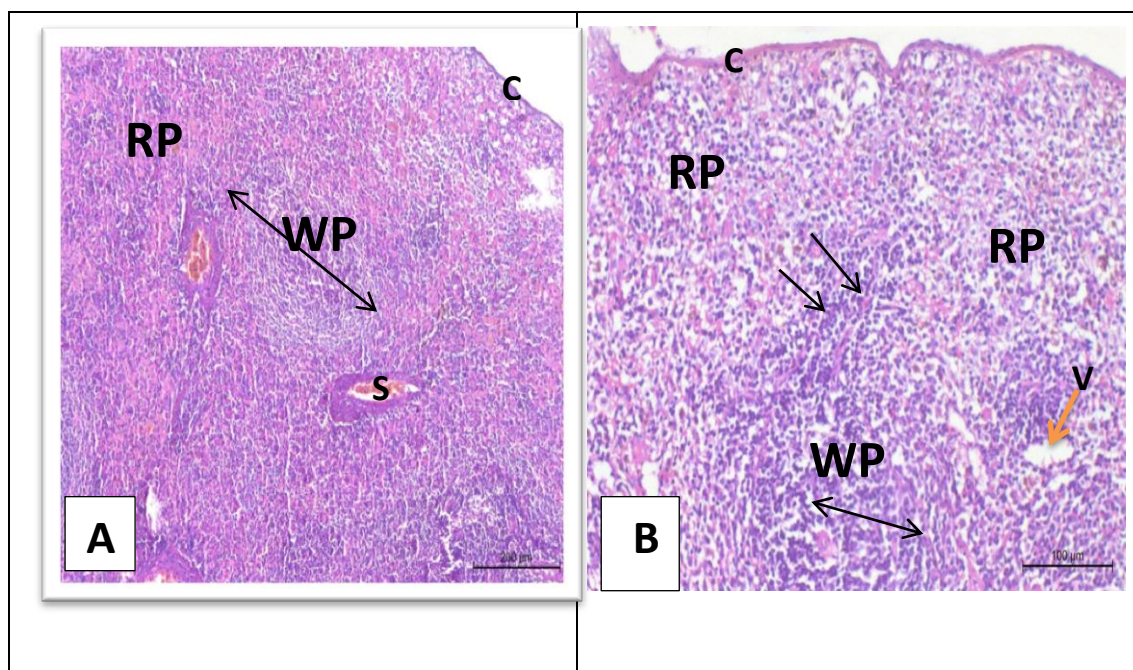
I) Histological results:

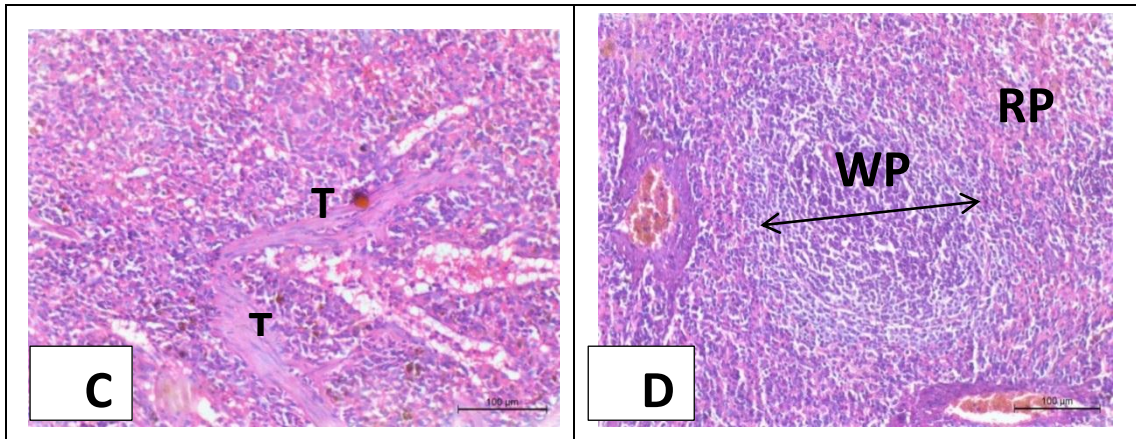
Examination of stained sections of the spleen with Hx&E of the control group showed presence of normal architecture of the spleen (thin capsule (C), red pulp (RP) and white pulp (WP) (**Fig.A**).

After addition of ZnO NPs, the normal architecture of the spleen is distorted, group

II, III, IV showed (deformed white pulp (**Fig.B**) thickening of the capsule and trabeculae and expansion of red pulp (**Fig.C**), So there was mild to massive loss of the normal architecture of the spleen and increased vacuolations with in the tissue (**Fig.B**) especially with high dose of ZnO NPs.

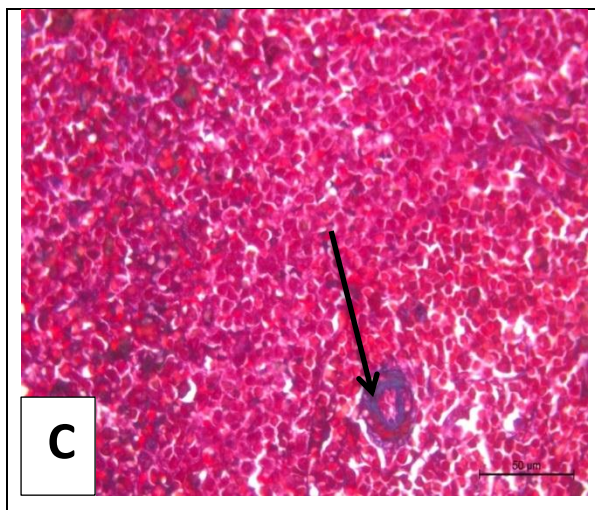
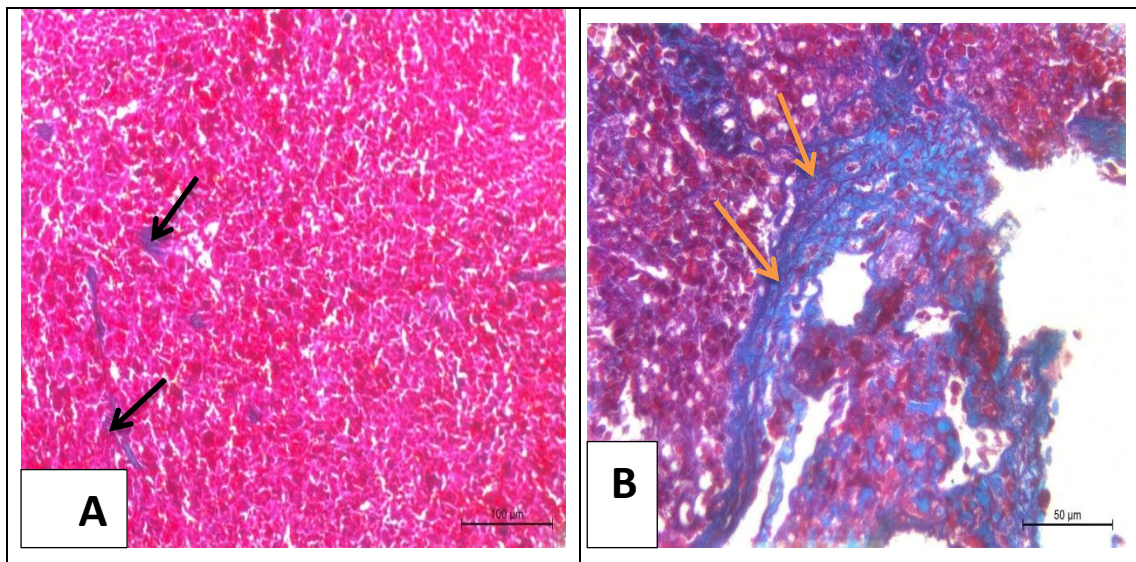
In group V, VI, VII, Concomitant treatment with selenium effectively inhibited the ZnO NPs induced splenic damage and succeeded in restoring the integrity of the spleen induced by ZnO NPs by H and E stained sections (**Fig. D**).





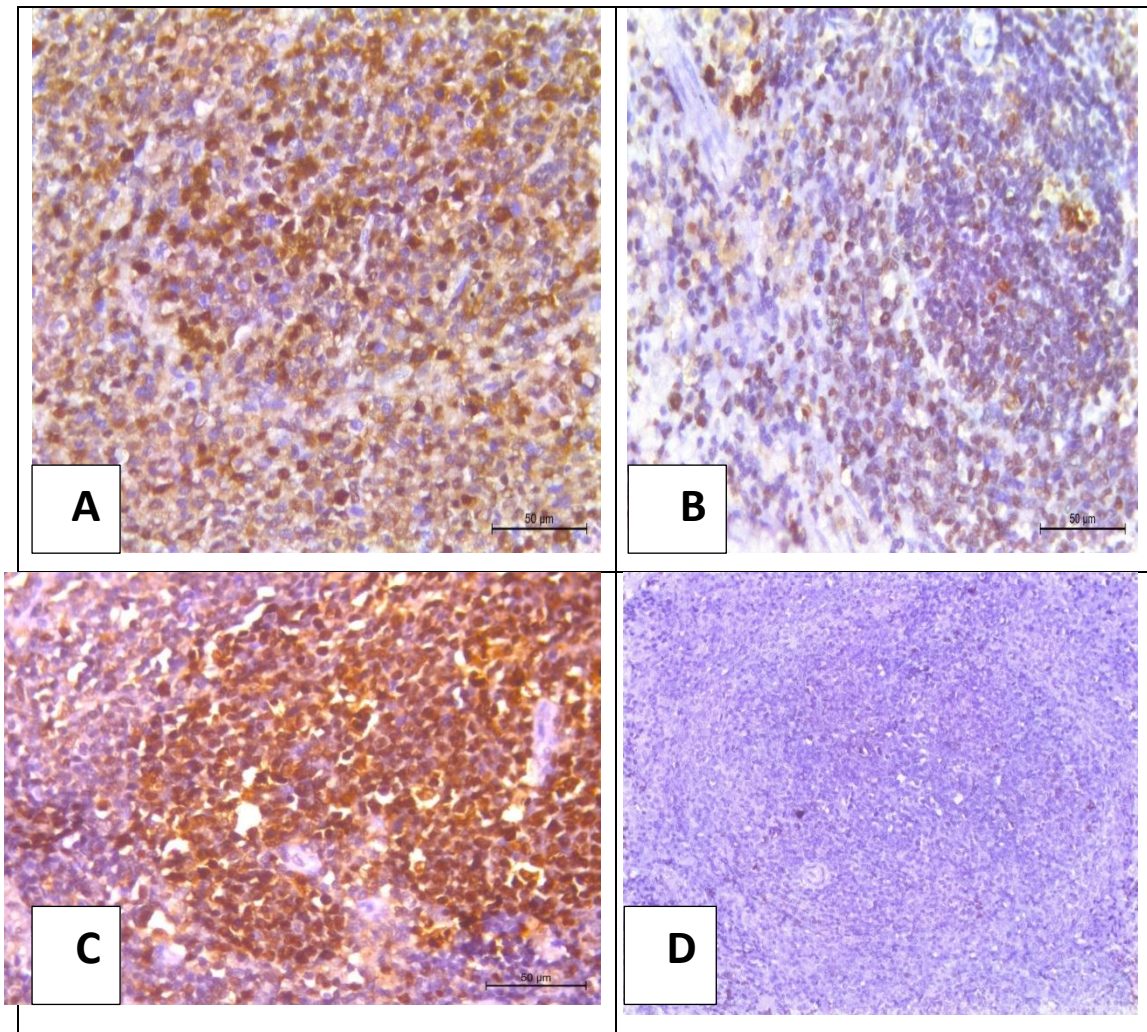
The stained section of control group with masson's trichrome showed collagen distribution was minimal around central arterioles and trabeculae (**Fig.A**).

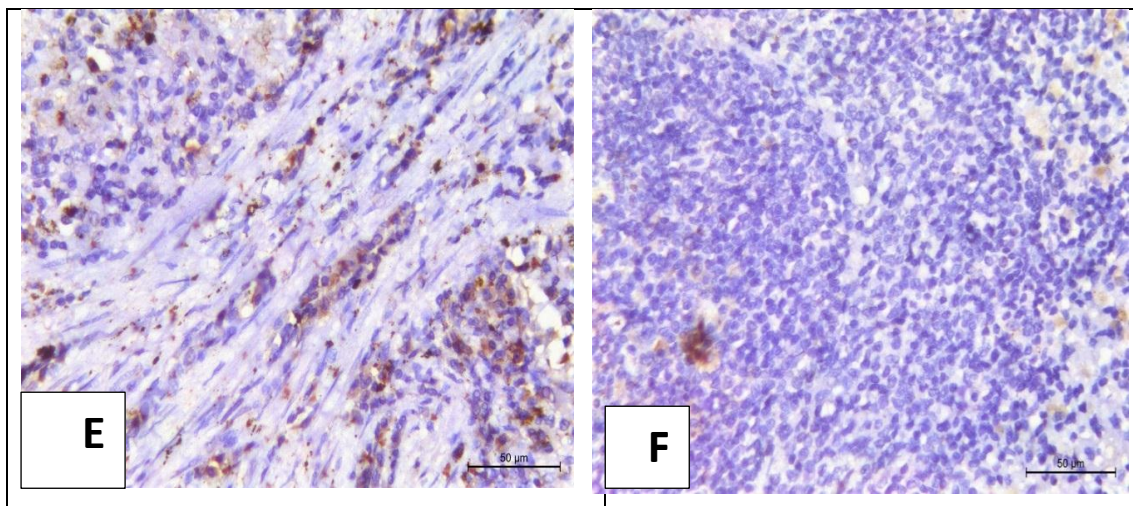
Results of groups II, III, IV after addition of ZnO NPs showed increased collagen deposition (**Fig.B**) but groups V, VI, VII, concomitant treatment with selenium Masson's trichrome sections showed decrease collagen deposition again (**Fig.C**).



The stained section of control group was characterized by strong positive brown immunorexpression of (PCNA) in most splenocytes of of the white pulp as well as in the red pulp (**Fig.A**), Also a weak positive brown immunorexpression of (p53) in a few numbers of cells in the RP while in the WP (**Fig.D**).

Results of groups II, III, IV after addition of ZnO NPs showed strong P53 immunoreaction (**Fig.E**) and weak PCNA (**Fig.B**) immunoreaction. But in groups V, VI, VII, concomitant treatment with selenium showed weak P53 immunoreaction (**Fig.F**) and strong PCNA immunoreaction again(**Fig.C**).



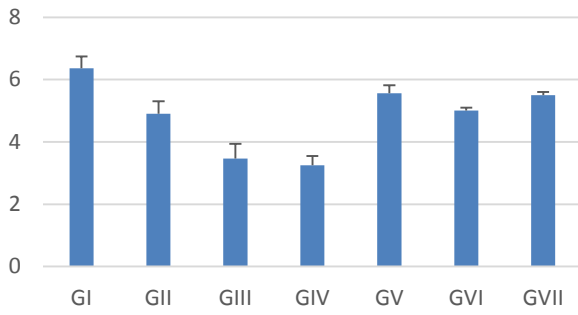


II) Biochemical results:

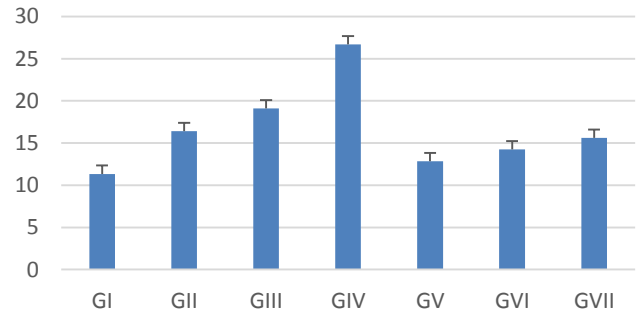
There was significant decrease in red blood cells, platelets counts, paraoxonase-1 (PON-1) and mean area percentage of PCNA in ZnO-NPs groups (group II, III, IV) compared to the control group. There was significant increase in red blood cells, platelets counts, paraoxonase-1 (PON-1) and mean area percentage of PCNA in ZnO-NPs & se groups (groups V, VI, VII).

There was significant increase in white blood cells count, Hydrogen peroxide (H₂O₂), caspase-3 level, Apoptosis inducing factor(AIF), Apoptotic protease activating factor-1(APAF-1), zinc level and mean area percentage of both P53 and masson's Trichome in ZnO-NPs groups (group II, III, IV) compared to the control group where there was significant decrease in white blood cells count, Hydrogen peroxide (H₂O₂), caspase-3 level, Apoptosis inducing factor(AIF), Apoptotic protease activating factor-1(APAF-1), zinc level and mean area percentage of both P53 and masson's Trichome in ZnO-NPs & se groups (group S V, VI, VII) again.

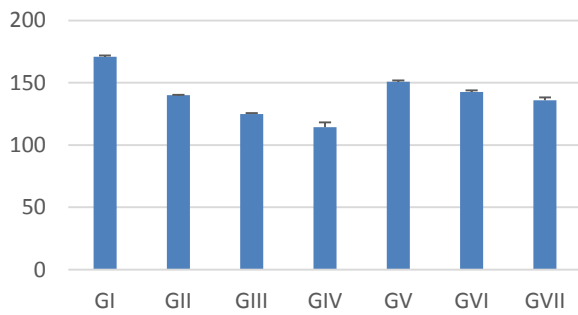
RBCs



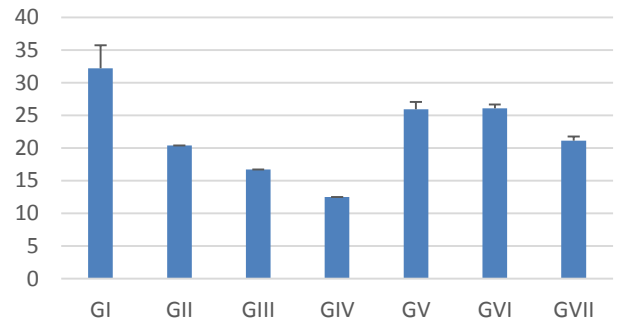
WBCs



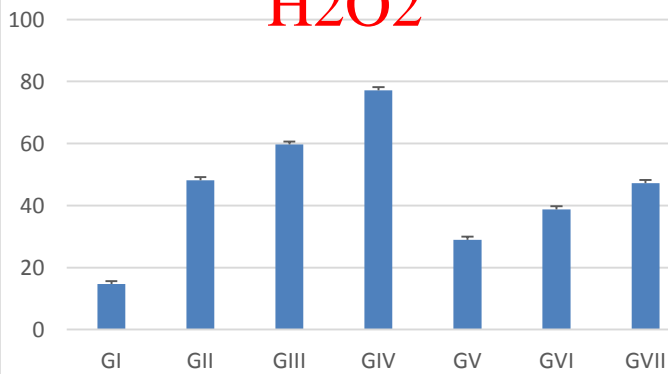
Plateletes



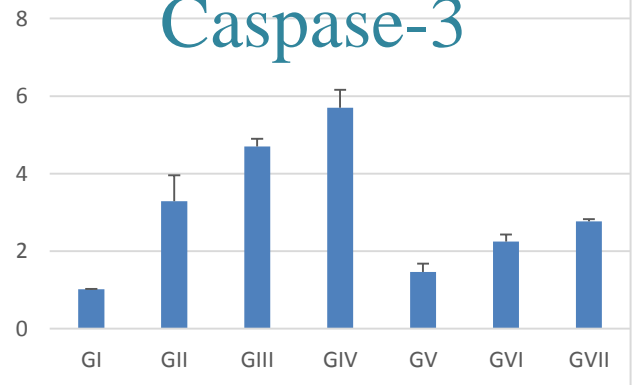
PON-1

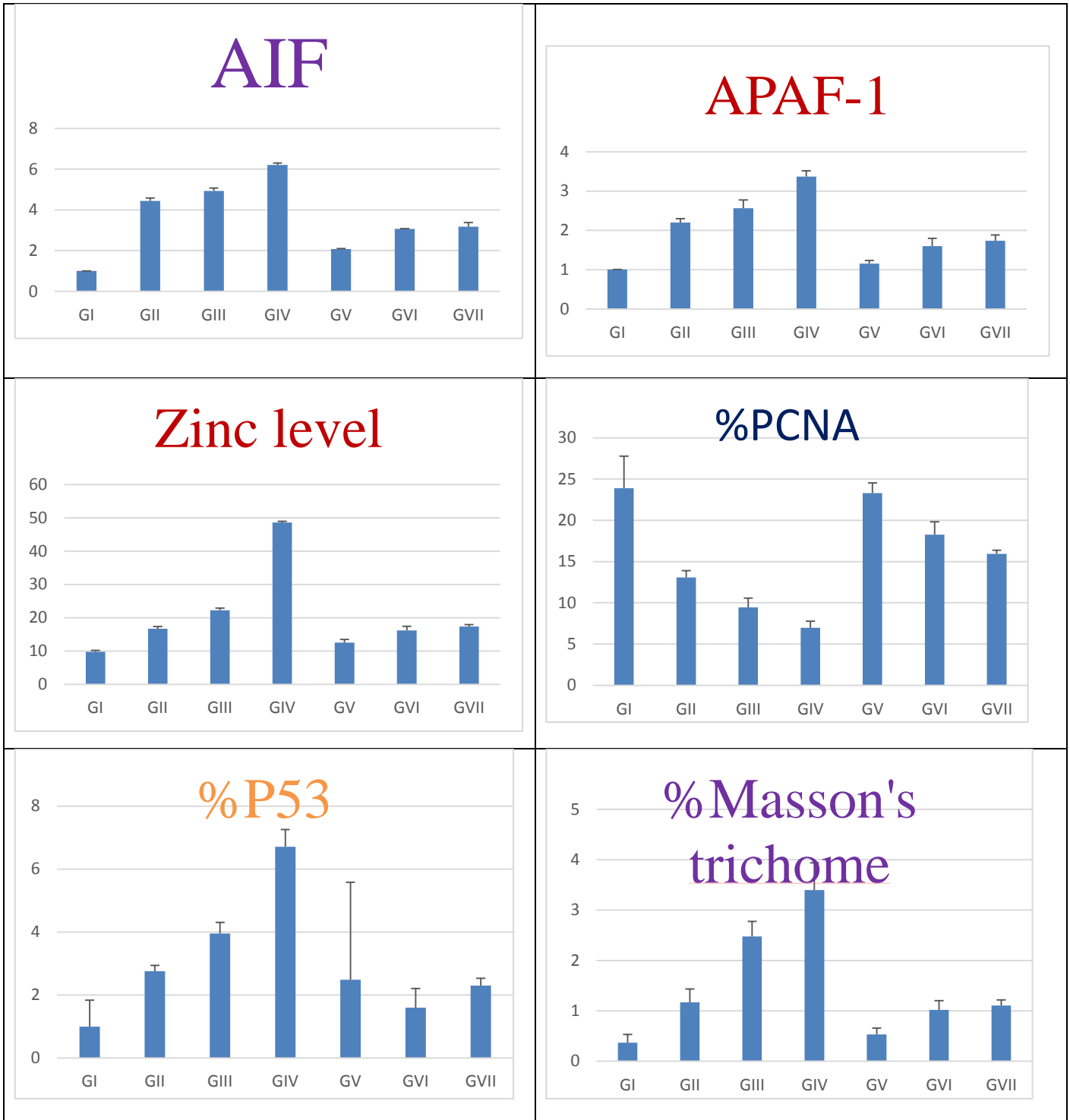


H2O2



Caspase-3





4. Discussion:

This work was performed to study the possible toxic effects of oral administration of ZnO NPs for 2 weeks in rat's spleen. (13) The presence of toxic metals in food products has become a global problem. ZnO NPs is one of the most important metal

oxide nanoparticles and they are popularly employed in various fields due to their unique chemical and physical properties (14, 15)

Nano-ZnO, makes zinc more easily to be absorbed by the body due to small particle size, thus nano-ZnO is commonly used as a food additive. In the present work, the oral route administration was chosen as it is the main mode of exposure to ZnO NPs in humans and animals (16)

The spleen is not only an organ that serves as the largest blood filter in the body, it also plays an important role in the immune system and shares responsibility for a variety of other areas, including defending the body from invading bacteria, identifying, removing unwanted damaged or aberrant cells, preventing the development of tumours and mitigating various other forms of diseases. (17).

In the current study we detect the protective role of selenium as one of important factors for reducing ZnO NPs toxicity. (18) Selenium is considered an essential element for humans and animals and Se is also known for its antioxidant role in living systems.

The current study shows that, in the ZnO NPs groups there was atrophy of white pulps with disappearance of germinal centers, expanded red pulp, thickened stroma, also vacuolation and apoptosis of some splenocytes were revealed. (19) reported the same observations on splenocytes and (20) documented atrophy of hepatocytes after ZnO NPs exposure.

Our study stated also degeneration of the white pulp in the spleen and cellular disruption as compared to the control sections, in agreement with (21) documented the administration of magnesium nanoparticles-induced degenerative and atrophic changes in the rat spleen due to induced oxidative stress, inflammation, and histopathological changes in the spleen like ZnO NPs.

As regard Masson's trichrome stain, in the present study of rat's spleen exposed to ZnO NPs showed massive deposition of collagen in the capsule, trabeculae, the interstitial tissue and around central arteriole especially in high dose of ZnO NPs and we referred that to massive fibrosis associated with ZnO NPs especially after oxygen free radicals formation. These results are in agreement with that of (22)

Also animals that received high dose of ZnO-NP showed marked increase of deposition of collagen fibers in the interstitial tissue and this histopathological change coincided with the results of (23) study, These findings were confirmed by the morphometrical and statistical results; there was a significant increase in the area percentage of trichrome-stained collagen in ZnO NPs groups, in comparison with control group.

So in our study we evaluated the effects of the ZnO NPs on cell proliferation by PCNA immunostaining, as PCNA is currently

reported to have functions in kinetics of cell cycle and consequently a good marker for proliferating cell as reported by (24).

Groups that received ZnO NPs revealed a decrease in immunopositive stained cells. Similar result observed in treatment of a human gastric adenocarcinoma with ZnO NPs documented a significant inhibition of cellular proliferation, also in the line with (25).

As p53 is a tumor suppressor gene that plays an important role in cell cycle control, aging and apoptotic response to radiation and other causes of cell damage (26). In this work, apoptosis was evident by immunodetection of P53 in the ZnO NPs spleen. (27) Reported that ZnO NPs is a genotoxic material. It can stimulate DNA damage or causes direct DNA lesions. We evaluated the effects of the ZnO NPs as apoptotic factor by P53 immunostaining. Consequently, in our study P53 is up regulated with a concomitant arresting of the cell cycle and initiation of apoptosis supported by (28).

These findings were confirmed by the morphometrical and statistical results; there was a significant decrease in the area percentage of PCNA ZnO NPs groups in comparison with the control group I, and there was a significant increase in the area percentage of P53 in ZnO NPs groups, in comparison with the control group.

In our study we used selenium as protective against ZnO NPs in agreement with (29) as Selenium (Se) was chosen due to its good chemical property and ease of synthesis of Se- doped ZnO.

Also ZnO NPs cause damage and resulting in increasing oxygen free radicles, reactive oxygen species (ROS),in contrast with selenium which it plays an important role in the formation of several important types of selenoproteins such as glutathione peroxidase and thioredoxin reductase (30) and protects the body against oxidative stress (31).

In our study there was significant decrease of RBCs count especially with increasing the dose of ZnO NPs, we referred that to Zn ions release is higher. The higher concentration of metal ions may be the possible reason for increasing hemolysis of RBCs which observed in present study in agreement with (32). Also this result supported by (33) suggested that gold NPs have an effect on the inflammatory response by changing the RBC levels.

Several studies corroborate our findings that smaller size nanoparticles show higher toxicity compared to larger particles, as small size nanoparticle easily cross the membrane because of higher surface area and it can strongly interact with biomolecule also supported by (34)

Corroboration with our findings is (35) Reported that ZnO NPs could induce anemia in mice via inhalation (36).

Also hematological analysis of ZnO NPs groups revealed beside decreased RBCs there was increased numbers of WBCs, decreased platelets count and These findings are in agreement with (37) who attributed the increased WBCs number to the inflammatory reaction induced by ZnO NPs. (34) found that the total WBCs counts increased significant and the marked decline in Hb% after ZnO NPs ingestion did not improve following 14 days recovery period.

So we used selenium as it improves the haematological indices in agreement with (39,38) who also confirmed the role of selenium in improving the haematological indices in other species like fishes ,also Selenium nanoparticle supplementation positively enhanced the innate immunity by improving the serum lysozyme activity (40)

In the present study, the level of caspase-3 was measured to detect apoptosis, our finding showed marked increase especially with high dose ZnO NPs group, this upregulation of caspase-3 also has been reported (41).

Thus, ZnO-NPs markedly activate caspase-3 and caspase-9 in a time-response, which is consistent with the outcomes of other studies that have shown a number of prepared nanoparticles induce apoptosis through the

activation of procaspases and the mitochondrial intrinsic pathway(42).

In this study we were keen to detect oxidative stress as oxidative stress is considered one of the causative factors of apoptosis in pathogenesis and aggressiveness of most cancers (43). our finding showed noticeable increase of H₂O₂ as one of stress factor and we explained the finding due to alteration in antioxidant enzyme activities with reduction of serum total antioxidant capacity, in agreement with (44) who also observed the altered erythrocyte antioxidant enzyme activities, increased in malondialdehyde (MDA) production, and marked reduction of antioxidant capacity related to ZnO exposure.

Also other explanation to elevated level of H₂O₂ with ZnO was the study of (45) as Producing Radical Oxygen Species (ROS) by ZnO act as semiconductor with a wide band gap. Moreover, free electron in the conduction band creates a superoxide ion in the presence of oxygen, which can become a hydroxyl radical as well.

Therefore, the generation of all derivatives of active oxygen is considered important which can destroy the bacterial cell (46).

The results of our study showed lower activities of PON-1 in all the studied ZnO NPs groups compared to normal control, in accordance with (47) revealed a decrease in

serum antioxidant enzyme (PON-1) levels in diabetic rats treated with ZnO NPs.

Current study showed noticeable increase in AIF level analogous to (48) who reported that apoptosis-inducing factor (AIF) was also up-regulated by NPs and released from the mitochondria to the cytoplasm.

Also our study reported significant increase in the level of APAF-1 as one of the apoptotic factor during exposure to ZnO NPs, the latter induce Accumulation of intracellular ROS also cause activation of the caspase cascade, and ultimately to programmed cell death through apoptosis, our study in agreement with (49). ROS formation and this imbalance occurred resulting in releasing apoptotic factors like AIF, APAF-1 and caspase-3 (50).

In this study we were keen to measure zinc level in the splenic tissue, our finding demonstrated accumulation of zinc especially with high dose ZnO NPs. (37) reported that the Zn concentration dose-dependently increased in the liver, kidneys and intestine compared with the control group.

Not only spleen but most of organ showed accumulation of zinc after of orally exposed ZnO-NPs in agreement with (51) demonstrate that most organs were the target of orally exposed ZnO-NPs and ZnO sub-microparticles.

5. Conclusion:

Selenium have a great protective impact against toxicity ZnO NPs on the spleen through their effect in decreasing collagen deposition also the presence of Selenium documented beneficial effects on histological changes after exposure to ZnO NPs. This proves that Selenium play a significant role in ZnO NPs toxicity. So the administration of antioxidants in response to an increased risk of exposure to ZnO NPs compounds may protect the human body against their harmful effects. Although Selenium was able to restore the cell structure and prevent cellular damage, further investigations using different doses of both ZnO NPs and selenium, Selenium NPs are required.

6. References:

1. Boverhof, D. R., Bramante, C. M., Butala, J. H., Clancy, S. F , Lafranconi, M. et al. (2015): Comparative assessment of nanomaterial definitions and safety evaluation considerations. *Regul. Toxicol. Pharmacol.* 73, 137–150
2. Eastlake, A., Zumwalde, R., and Geraci, C. (2016): Can control banding be use-ful for the safe handling of nanomaterials? A systematic review. *J. Nanopar-ticles Res.* 18, 169. Pii
3. Sapsford, K. E., Algar, W. R., Berti, L., Gemmill, K. B., Casey, B. J., et al(2013): Functionalizing nanoparticles

- with biological molecules: developing chemistries that facilitate nanotechnology. *Chem. Rev.* 113, 1904–2074.
4. Yokel, R. A. and MacPhail, R. C. (2011): Engineered nanomaterials: exposures, hazards, and risk prevention. *J. Occupat. Med. Toxicol.*
 5. Cho, W. S., Duffin, R., and Thielbeer, F. (2012): Zeta potential and solubility to toxic ions as mechanisms of lung inflammation caused by metal/metal oxide nanoparticles. *Toxicol. Sci.* 126, 469–477 .
 6. Mansouri, E., Khorsandi, L., Orazizadeh, M., and Jozi, Z. (2015): Dose-dependent hepatotoxicity effects of Zinc oxide nanoparticles. *Nanomed. J.* 2, 273-282
 7. Gojova, A., Guo, B., Kota, R. S., Rutledge, J. C., Kennedy, I. M., et al. (2007): Induction of inflammation in vascular endothelial cells by metal oxide nano-particles: effect of particle composition. *Environ. Health Perspect.* 115, 403,409
 8. Tapiero, H, Townsend, D.M and Tew, K.D(2003): The antioxidant role of selenium and seleno-compounds. *Biomed Pharm.*;57:134–44
 9. Pandurangan, M., and Kim, D. H. (2015): In vitro toxicity of zinc oxide nano-particles: a review. *J. Nanoparticle Res.* 17, 1–8
 10. Sharma, V., Singh, P., Pandey, A. K. and Dhawan, A. (2012): Induction of oxidative stress, DNA damage and apoptosis in mouse liver after sub-acute oral exposure to zinc oxide nanoparticles. *Mutation Research/Genetic Toxicology and Environmental Mutagenesis*, 745(1), 84-91.
 11. Viezeliene, D., Jansen, E., Rodovicius, H., Kasauskas, A. and Ivanov, L. (2011): Protective effect of selenium on aluminium-induced oxidative stress in mouse liver in vivo. *environmental toxicology and pharmacology*, 31(2), 302-306.
 12. Bancroft, J. D., & Gamble, M. (Eds.). (2018): *Theory and practice of histological techniques*. Elsevier health sciences.
 13. Winiarska-Mieczan, A. (2018): Protective effect of tea against lead and cadmium-induced oxidative stress—a review. *Biometals*, 31(6), 909-926.
 14. Smijs, T. G., & Pavel, S. (2011): Titanium dioxide and zinc oxide nanoparticles in sunscreens: focus on their safety and effectiveness. *Nanotechnology, science and applications*, 4, 95.
 15. Ruszkiewicz, J. A., Pinkas, A., Ferrer, B., Peres, T. V., Tsatsakis, A., & Aschner, M. (2017): Neurotoxic effect of active ingredients in sunscreen products, a contemporary review. *Toxicology Reports*, 4, 245-259.

16. M Herranz, L., Teba, F., Martin, R., Ingelmo, I., Gomez, V., Codesal, J., & Santamaría, L. (2010): Quantitative changes in rat seminiferous epithelium after chronic administration of low doses of cadmium and zinc: A stereological study. *The Open Andrology Journal*, 2(1).
17. Wluka, A., & Olszewski, W. L. (2006): Innate and adaptive processes in the spleen. *Annals of transplantation*, 11(4), 22-29.
18. Mohamed, H. Z., Ragab, I. K., & Ghafeer, H. H. (2016): A histological study on the possible protective effect of selenium against chromium-induced thyrotoxicity in adult male albino rats. *The Egyptian Journal of Histology*, 39(1), 1-11.
19. Wang, B., Feng, W., Wang, M., Wang, T., Gu, Y., Zhu, M., & Chai, Z. (2008): Acute toxicological impact of nano-and submicro-scaled zinc oxide powder on healthy adult mice. *Journal of Nanoparticle Research*, 10(2), 263-276.
20. Mansouri, E., Khorsandi, L., Orazizadeh, M., & Jozi, Z. (2015): Dose-dependent hepatotoxicity effects of zinc oxide nanoparticles.
21. Ebaid, H. M., & Tag, H. M. (2012): Monosodium glutamate toxic effect on spleen structure and potentiality of recovery in adult Albino rats. *Egyptian Academic Journal of Biological Sciences, B. Zoology*, 4(1), 1-8.
22. Al-Rasheed, N. M., Baky, N. A., Faddah, L. M., Fatani, A. J., Hasan, I. H., & Mohamad, R. A. (2014): Prophylactic role of a-lipoic acid and vitamin E against zinc oxide nanoparticles induced metabolic and immune disorders in rat's liver. *Eur Rev Med Pharmacol Sci*, 18(12), 1813-1828.
23. Wang, B., Feng, W. Y., Wang, M., Shi, J. W., Zhang, F., Ouyang, H., & Wang, H. F. (2007): Transport of intranasally instilled fine Fe₂O₃ particles into the brain: micro-distribution, chemical states, and histopathological observation. *Biological trace element research*, 118(3), 233-243.
24. Zerjatke, T., Gak, I. A., Kirova, D., Fuhrmann, M., Daniel, K., Gonciarz, M & Mansfeld, J. (2017): Quantitative cell cycle analysis based on an endogenous all-in-one reporter for cell tracking and classification. *Cell reports*, 19(9), 1953-1966.
25. Kanter, M., Aktas, C., & Erbogaa, M. (2013): Curcumin attenuates testicular damage, apoptotic germ cell death, and oxidative stress in streptozotocin-induced diabetic rats. *Molecular nutrition & food research*, 57(9), 1578-1585.
26. Lane, D. P. (1992): Cancer. p53, guardian of the genome. *Nature*, 358, 15-16.
27. Ng, K. W., Khoo, S. P., Heng, B. C., Setyawati, M. I., Tan, E. C., Zhao, X., ... & Loo, J. S. (2011): The role of the tumor suppressor p53 pathway in the cellular DNA damage response to zinc oxide nanoparticles. *Biomaterials*, 32(32), 8218-8225.
28. Meyer, K., Rajanahalli, P., Ahamed, M., Rowe, J. J., & Hong, Y. (2011): ZnO nanoparticles induce apoptosis in

- human dermal fibroblasts via p53 and p38 pathways. *Toxicology in vitro*, 25(8), 1721-1726.
29. Chaudhary, S., Umar, A., & Mehta, S. K. (2016): Selenium nanomaterials: an overview of recent developments in synthesis, properties and potential applications. *Progress in Materials Science*, 83, 270-329.
30. Burk, R. F., & Hill, K. E. (1993): Regulation of selenoproteins. *Annual review of nutrition*, 13(1), 65-81
31. Yu, K. N., Yoon, T. J., Minai-Tehrani, A., Kim, J. E., Park, S. J., Jeong, M. S., & Cho, M. H. (2013): Zinc oxide nanoparticle induced autophagic cell death and mitochondrial damage via reactive oxygen species generation. *Toxicology in Vitro*, 27(4), 1187-1195.
32. Ng, A. M. C., Chan, C. M. N., Guo, M. Y., Leung, Y. H., Djurišić, A. B., Hu, X., ... & Tong, S. Y. (2013): Antibacterial and photocatalytic activity of TiO₂ and ZnO nanomaterials in phosphate buffer and saline solution. *Applied microbiology and biotechnology*, 97(12), 5565-5573.
33. Zhang, X. D., Di Wu, X. S., Liu, P. X., Yang, N., Zhao, B., Zhang, H., ... & Fan, F. Y. (2011): Size-dependent in vivo toxicity of PEG-coated gold nanoparticles. *International journal of nanomedicine*, 6, 2071.
34. Chen, L. Q., Fang, L., Ling, J., Ding, C. Z., Kang, B., & Huang, C. Z. (2015): Nanotoxicity of silver nanoparticles to red blood cells: size dependent adsorption, uptake, and hemolytic activity. *Chemical research in toxicology*, 28(3), 501-509.
35. Liu, Z. H., Wang, X., Wang, H. F., Wang, T. C., Gu, Y. Q., Yan, L., & Zang, J. J. (2008): Acute toxicity of nano-sized Zn oxide in ICR mice via intratracheal instillation. *J Environ Occup Med*, 25(4), 360-364.
36. Li, C. H., Liao, P. L., Shyu, M. K., Liu, C. W., Kao, C. C., Huang, S. H., ... & Kang, J. J. (2012): Zinc oxide nanoparticles-induced intercellular adhesion molecule 1 expression requires Rac1/Cdc42, Mixed Lineage Kinase 3, and c-Jun N-Terminal kinase activation in endothelial cells. *Toxicological Sciences*, 126(1), 162-172.
37. Park, H. S., Kim, S. J., Lee, T. J., Kim, G. Y., Meang, E., Hong, J. S., & Kang, J. S. (2014): A 90-day study of sub-chronic oral toxicity of 20 nm positively charged zinc oxide nanoparticles in Sprague Dawley rats. *International journal of nanomedicine*, 9(Suppl 2), 93.
38. Molnár, T., Biró, J., Balogh, K., Mézes, M., & Hancz, C. (2012): Improving the nutritional value of Nile

- tilapia fillet by dietary selenium supplementation. *Israeli Journal of Aquaculture – Bamidgeh*, IJA_64.2012.744, 744–750.
39. El-Hammady, A., El-Kasheif, M., & Ibrahim, S. (2007): SYNERGISTIC REACTIONS BETWEEN VITAMIN E AND SELENIUM IN DIETS OF HYBRID TILAPIA (*OREOCHROMIS NILOTICUS* X *OREOCHROMIS AUREUS*) AND THEIR EFFECT ON THE GROWTH AND LIVER HISTOLOGICAL STRUCTURE. *Egyptian Journal of Aquatic Biology and Fisheries*, 11(1), 53-81.
40. Khan, K. U., Zuberi, A., Nazir, S., Fernandes, J. B. K., Jamil, Z., & Sarwar, H. (2016): Effects of dietary selenium nanoparticles on physiological and biochemical aspects of juvenile *Tor putitora*. *Turkish Journal of Zoology*, 40(5), 704-712.
41. Kao, Y. Y., Chen, Y. C., Cheng, T. J., Chung, Y. M., & Liu, P. S. (2012): Zinc oxide nanoparticles interfere with zinc ion homeostasis to cause cytotoxicity. *Toxicological Sciences*, 125(2), 462-472.
42. Rahman, H. S., Rasedee, A., Abdul, A. B., Zeenathul, N. A., Othman, H. H., Yeap, S. K., ... & Hafiza, W. A. G. W. N. (2014): Zerumbone-loaded nanostructured lipid carrier induces G2/M cell cycle arrest and apoptosis via mitochondrial pathway in a human lymphoblastic leukemia cell line. *International journal of nanomedicine*, 9, 527.
43. Curtin, J. F., Donovan, M., & Cotter, T. G. (2002): Regulation and measurement of oxidative stress in apoptosis. *Journal of immunological methods*, 265(1-2), 49-72.
44. Nazarizadeh, A., & Asri-Rezaie, S. (2016): Comparative study of antidiabetic activity and oxidative stress induced by zinc oxide nanoparticles and zinc sulfate in diabetic rats. *AAPS PharmSciTech*, 17(4), 834-843.
45. Yamamoto, O. (2001): Influence of particle size on the antibacterial activity of zinc oxide. *International Journal of Inorganic Materials*, 3(7), 643-646.
46. Song, W., Zhang, J., Guo, J., Zhang, J., Ding, F., Li, L., & Sun, Z. (2010): Role of the dissolved zinc ion and reactive oxygen species in cytotoxicity of ZnO nanoparticles. *Toxicology letters*, 199(3), 389-397.
47. Hussein, J., El-Banna, M., Razik, T. A., & El-Naggar, M. E. (2018): Biocompatible zinc oxide nanocrystals stabilized via hydroxyethyl cellulose for mitigation of diabetic complications. *International journal of*

- biological macromolecules*, 107, 748-754.
48. Zhao, J., Bowman, L., Zhang, X., Shi, X., Jiang, B., Castranova, V., & Ding, M. (2009): Metallic nickel nano-and fine particles induce JB6 cell apoptosis through a caspase-8/AIF mediated cytochrome c-independent pathway. *Journal of nanobiotechnology*, 7(1), 2.
49. Jing, Y., Dai, J., Chalmers-Redman, R. M., Tatton, W. G., & Waxman, S. (1999): Arsenic trioxide selectively induces acute promyelocytic leukemia cell apoptosis via a hydrogen peroxide-dependent pathway. *Blood, the Journal of the American Society of Hematology*, 94(6), 2102-2111.
50. Sabour-Pickett, S., Nolan, J. M., Loughman, J., & Beatty, S. (2012): A review of the evidence germane to the putative protective role of the macular carotenoids for age-related macular degeneration. *Molecular nutrition & food research*, 56(2), 270-286.
51. Faddah, L. M; Abdel Baky, N. A; Mohamed, A. M; Al-Rasheed, N. M; Al-Rasheed, N. M. J. (2013): Nanopart. Res. 15:1520.